

<h1>IMAGES</h1>	<b>in</b> <b>PAEDIATRIC</b> <b>CARDIOLOGY</b>
-----------------	---

Images Paediatr Cardiol. 1999 Jan-Mar; 1(1): 3–13.

PMCID: PMC3232475

## **Interpretation of electrocardiograms in infants and children**

M Tipple\*

\**Paediatric Cardiologist, British Columbia Children's Hospital and Clinical Professor, University of British Columbia*

**Contact information:** Dr. Marion Tipple, Paediatric ECG of the Week, Clinical Professor, British Columbia Children's Hospital, University of British Columbia ; Email: marion\_tipple@paedcard.com

Copyright : © Images in Paediatric Cardiology

This is an open-access article distributed under the terms of the Creative Commons Attribution-Noncommercial-Share Alike 3.0 Unported, which permits unrestricted use, distribution, and reproduction in any medium, provided the original work is properly cited.

### **Abstract**

Electrocardiography is a useful tool in the management of paediatric heart disease. Interpretation requires practice due to changing norms which are brought about by the physiological changes that occur in the circulatory system in this age group. This article outlines these normal changes.

**MeSH:** Electrocardiography, Diagnostic techniques and procedures, Heart defects, congenital

## 1. The Normal Electrocardiogram

As the child develops from the foetus to the neonate, infant, child, adolescent and adult, growth and development result in major changes of body size and shape, and with this the size and position of the heart relative to the body and cardiac physiology.

The most dramatic of these changes occur at birth and within the first year of life. In order to be able to interpret paediatric electrocardiograms (ECGs) it is therefore imperative, to have an understanding of these events.

Prior to birth, the ventricular pressures are equal and the pulmonary resistance is higher than the systemic, resulting in the right ventricular (RV) size and mass being larger than the left ventricular (LV) from 35 weeks gestation.

The placenta which receives 55% of the combined cardiac output provides a low resistance circuit to the systemic circulation. Right to left shunting occurs from the pulmonary artery to aorta via the patent ductus arteriosus (PDA) and from the right atrium to the left atrium via the foramen ovale. The small pulmonary arteries have more muscle than the small systemic arteries and pulmonary vasoconstriction further elevates the pulmonary resistance.

The dramatic changes at birth, with the removal of the low resistance placental circulation, the fall in pulmonary resistance as the lungs open and the functional (later permanent) closure of the PDA and foramen ovale, require significant physiological adaptation. Most of these changes occur rapidly over the first few hours and days of life but continue throughout the early childhood period and more gradually into adulthood. The left ventricle grows rapidly. By 1 month of age the LV/RV ratio has changed to 1.5:1 from the birth ratio 0.8:1, by 6 months 2:1 and then slowly to the adult ratio 2.5:1.

With these rapidly changing haemodynamics, one can expect the interpretation of the neonatal ECG to be the most challenging. There are many normal variables with a wide overlap from normal to abnormal. The less than 35 week gestation premature infant will have a different ECG from the full term infant. The normal infant ECG changes rapidly over the first few weeks of life and it is not until 3 years of age that it begins to resemble that of an adult. Significant differences, however, persist. Unless the interpreter is aware of these, the young patient is in danger of becoming an “electrocardiographic casualty” like several normal children I have seen with the ECG diagnosis of “acute myocardial infarction.”

In order to interpret paediatric electrocardiograms, the age of the patient and a table of normal values are essential. Davignon et al published the most recent values for a normal population. 2141 white children were divided into 12 different age groups, 7 within the first year of life.

## **Important Normal Variants**

### **T wave inversion:**

Infants older than 48 hours of age should have inverted T waves in the right praecordial leads. These findings persist throughout childhood with inversion to V4 being accepted as normal. There is a progressive change to an upright T wave across the praecordial leads from left to right as the child grows older. Until 8 years of age an upright T wave in V1 is considered a sign of right ventricular hypertrophy. Many children will show persistence of an inverted T wave in V1 until their late teens.

### **RSR' complex**

7% normal children under 5 years of age plus a few older children, will show an RSR' complex in the right praecordial leads. To be considered normal the width of the QRS should be no more than 10msec longer than normal and the R' voltage in V1 should be less than 15mm in infants under 1 year and less than 10mm over 1 year.

### **Elevated J point**

Early repolarization is commonly seen in adolescence with an elevated J point, most obvious in the mid praecordial leads. This is a completely normal finding and must be distinguished from pathological elevation of the ST segments.

## **Reading and Interpreting Electrocardiograms**

Unless the patient's age is known, the paediatric ECG cannot be interpreted. With the age in mind, the tracing may then be read objectively but to be interpreted fully additional clinical information is required, including:

1. Indication
2. Clinical diagnosis: cardiac and other
3. Medications: cardiovascular drugs, others eg. cisapride, tricyclics
4. Electrolytes

The electrocardiogram should be read systematically:

1. Heart rate
2. P wave axis
3. Rhythm
4. QRS axis
5. Intervals PR, QRS, QT/QTc
6. P wave amplitude and duration
7. QRS amplitude, R/S ratio, Q waves
8. ST segments and T wave

## Normal tracings

Examples of normal tracings for the different age groups follow, preceded by a general description of the characteristics of that age group.

### Premature infant (<35/40 gestation)

Relative tachycardia <200/min  
Relative LV dominance, less RV dominance  
P and QRS axis directed more left and posteriorly  
Shorter P, QRS, QT intervals  
Smaller R in V1, taller R in V6  
Taller T in V6  
More variability than the full term infant

### Full Term Newborn infant

Right axis deviation (up to +180)  
RV dominance in praecordial leads:  
- tall R in V1 (>10mm suggests RVH)  
- deep S in V6  
- R/S ratio >1 in right chest leads, relatively small in left  
QRS voltages in limb leads relatively small  
T waves – low voltage  
T wave in V1 maybe upright for < 48 hours (>48 hours suggests RVH)

### 1 week - 1 month

Right axis retained  
R waves remain dominant across to V6, although dominant S maybe normal  
T wave negative V1  
T wave voltage higher in limb leads

### 1 – 6 months

QRS axis rotates to leftward (less than +120)  
R wave remains dominant in V1  
R/S ratio in V2 close to I but maybe >1 in V1  
RSR' pattern in V1 not abnormal  
Large voltages in praecordial leads suggestive of BVH  
T waves negative across right chest leads

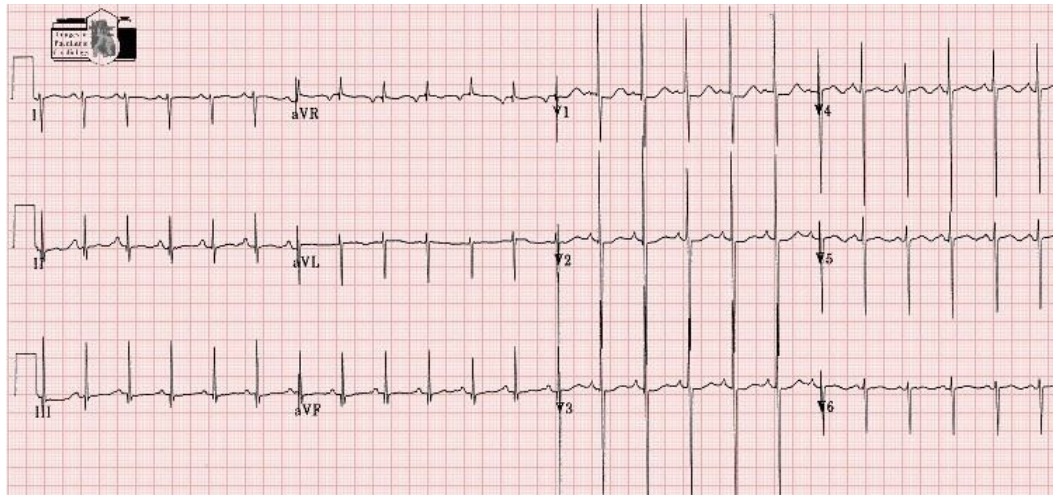
### 6 months – 3 years

QRS axis usually < +90  
R wave dominant in V6  
R/S ratio in V1 close to or less than 1  
Large voltages in praecordial leads persist

### 3 - 8 years

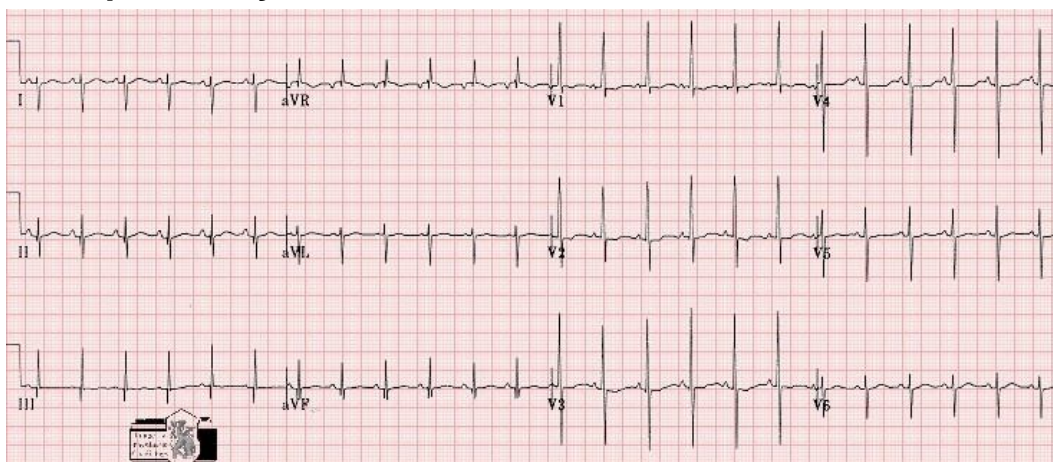
Adult QRS progression in praecordial leads: dominant S in V1, dominant R in V6  
Large praecordial voltages persist  
q waves in left chest leads may be large (< 5mm)  
T waves remain negative in right praecordial leads

### Example: 1 day old infant



Sinus rhythm. Heart rate 125. Axis 130  
PR 0.15. QRS 0.06. QT/QTc 0.28/0.40  
Upright T waves right chest leads  
Within normal limits for age

### Example: 2 day old infant



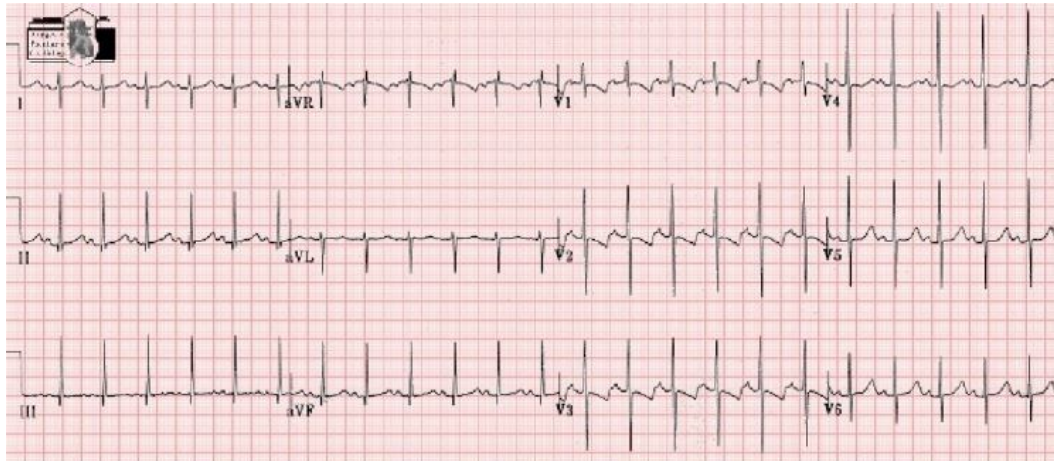Sinus rhythm. Heart rate 130. Axis +135  
PR 0.16. QRS 0.06. QT/QTc 0.28/0.41  
Dominant RV voltages. Biphasic T wave V1-4  
Within normal limits for age

#### 1 week to 1 month

Right axis retained  
R waves remain dominant across to V6, although dominant S maybe normal  
T wave negative V1  
T wave voltage higher in limb leads



### Example: 3 week old infant

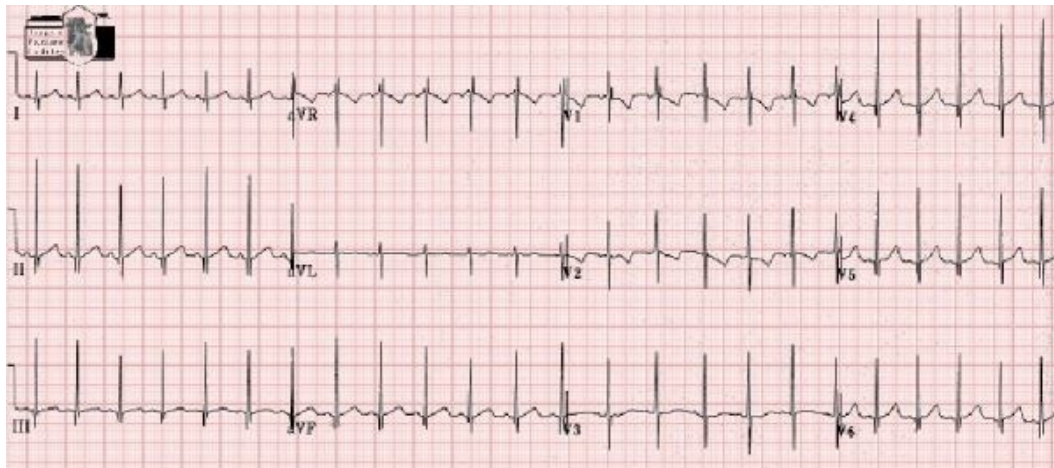


Sinus rhythm. Heart rate 125. Axis +100  
PR 0.12. QRS 0.06. QT/QTc 300/430  
Normal ECG for age

#### 1 - 6 months

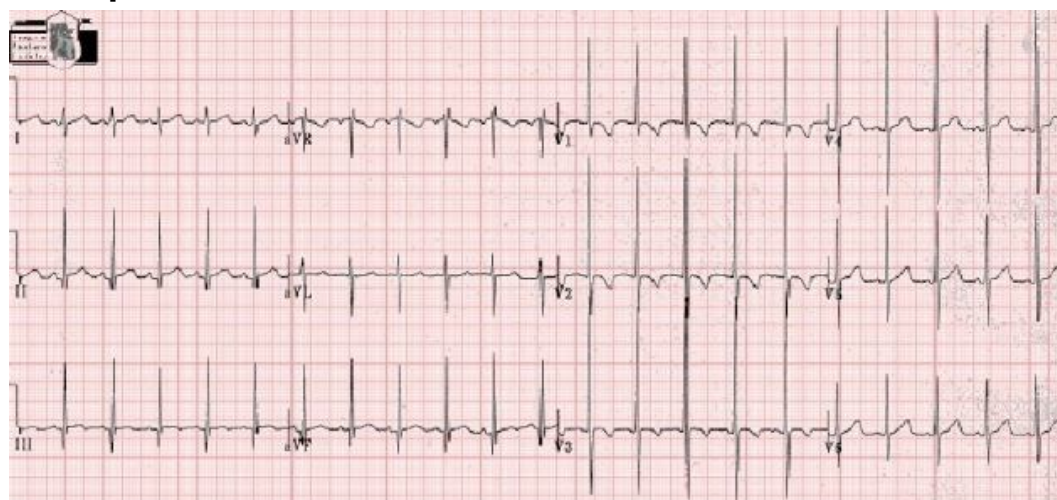QRS axis rotates to leftward (less than +120)  
R wave remains dominant in V1  
R/S ratio in V2 close to 1 but maybe >1 in V1  
RSR' pattern in V1 not abnormal  
Large voltages in precordial leads suggestive of BVH  
T waves negative across right chest leads

### Example: 2 month old infant



Sinus rhythm. Heart rate 150. QRS axis +80  
PR 0.08. QRS 0.06. QT / QTc 0.25/0.4  
RSR' pattern V1  
Normal tracing for age

### Example: 3 month old infant



Sinus rhythm. Heart rate 130. QRS axis +90

PR 0.10. QRS 0.08. QT/QTc 0.28/0.40

Normal tracing for age

**6 months – 3 years**

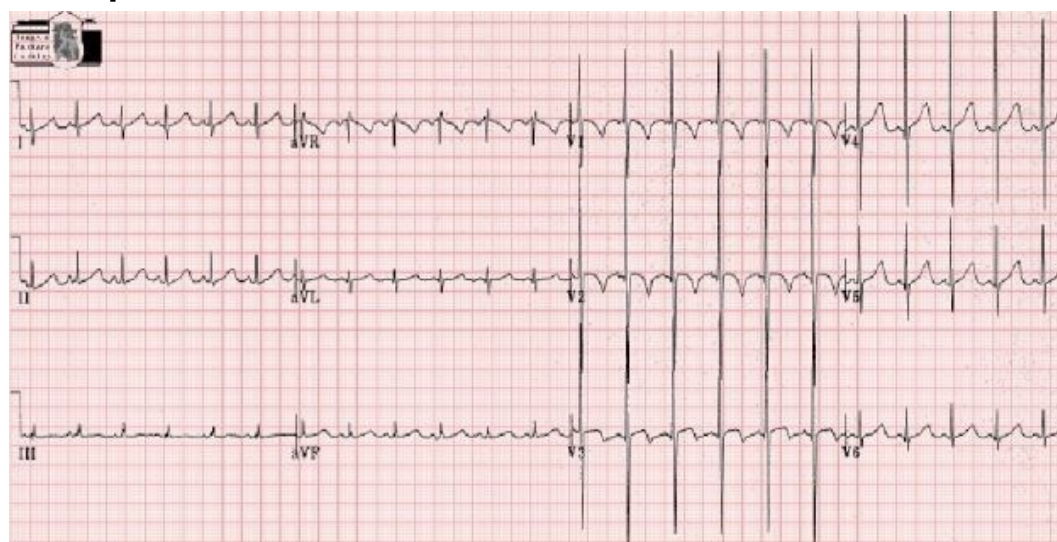
QRS axis usually < +90

R wave dominant in V6

R/S ratio in V1 close to or less than 1

Large voltages in precordial leads persist

### Example: 8 month old infant



Sinus rhythm. Heart rate 140. QRS axis + 60

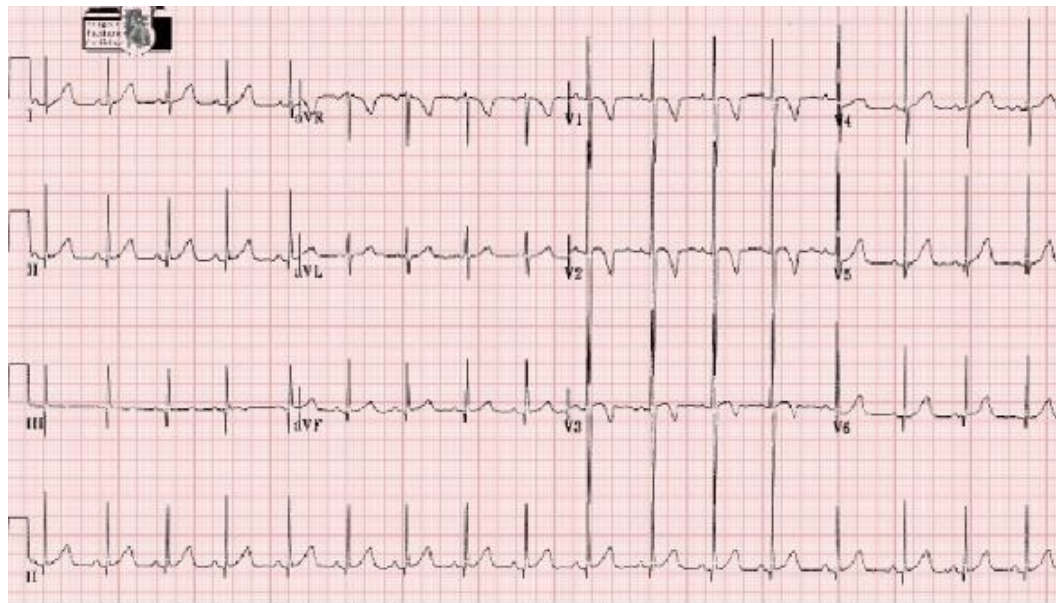PR 0.10. QRS 0.06. QT/QTc 0.28/0.42

Prominent precordial voltages

Normal for age

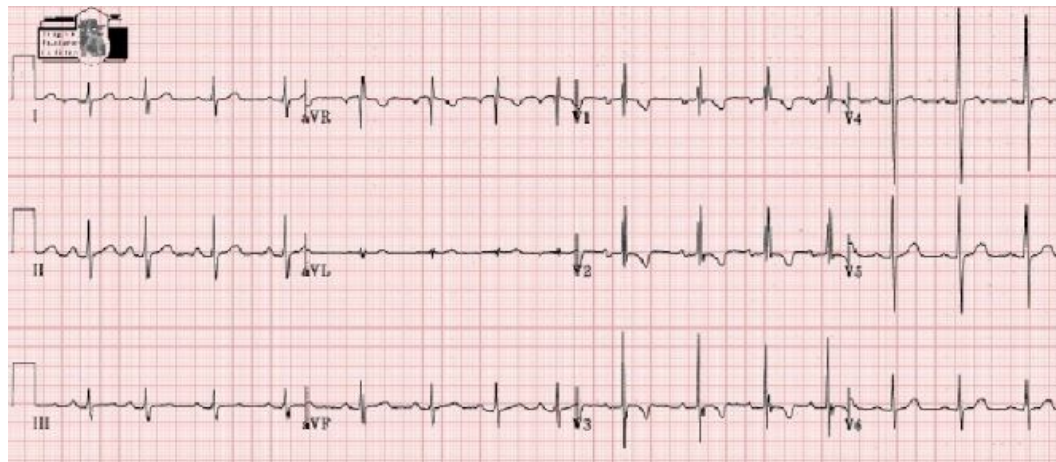


### Example: 23 month old female



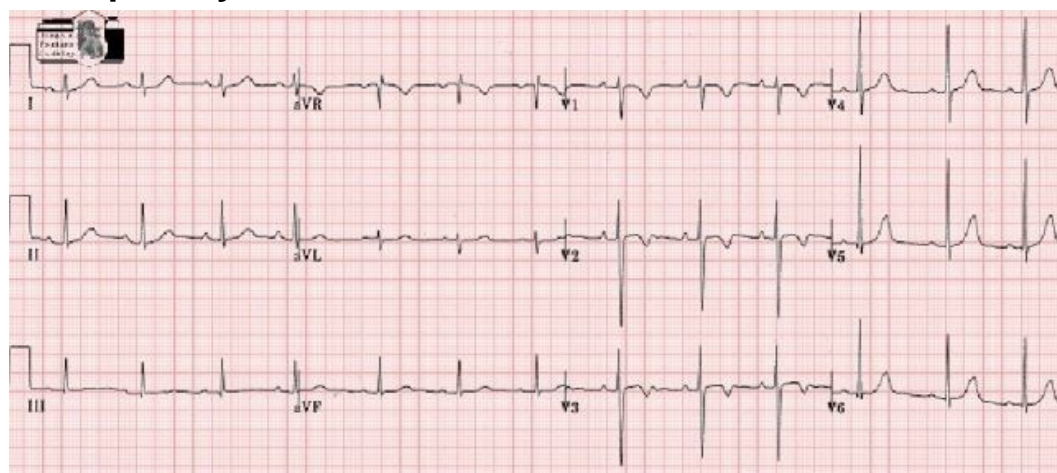
Sinus rhythm. Heart Rate 94. QRS axis +60  
PR 0.12. QRS 0.08. QT/QTc 0.32/0.37  
Normal electrocardiogram

### Example: 2 year old female



Sinus rhythm. Heart rate 80. QRS axis +80  
PR 0.18. QRS 0.08. QT 0.36  
RV conduction delay. (R' = 8mm)  
Within normal limits for age  
**3 - 8 years**  
Adult QRS progression in precordial leads: dominant S in V1, dominant R in V6  
Large precordial voltages persist  
q waves in left chest leads may be large (< 5mm)  
T waves remain negative in right precordial leads

### Example: 6 year old female

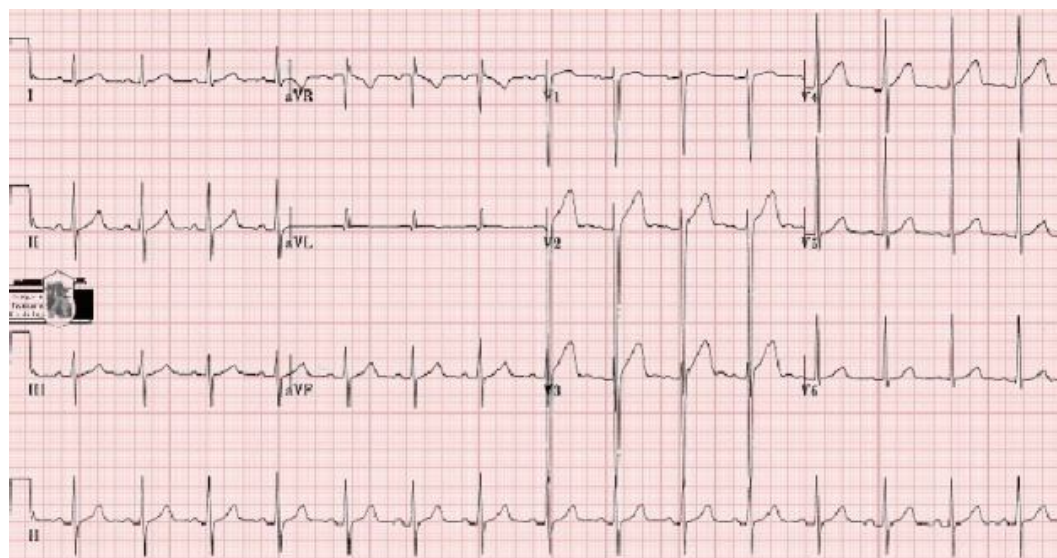


Sinus rhythm. Heart rate 75. QRS axis +88.  
PR 0.18. QRS 0.06. QT/QTc 0.36/0.40  
Normal for age

#### 8 – 16 years

QRS axis mean +60, range 0 to +90  
Adult QRS progression  
Large praecordial lead voltages, R in left leads larger than adult  
High J point  
T waves variable. Maybe upright in V1 but negative V1-V4 not abnormal

### Example: 15 year old male



Sinus rhythm. Heart Rate 75-80. Axis 0  
PR 0.18. QRS 0.08. QT 0.38/0.43  
Left axis. Deep posterior praecordial voltages  
Elevated J point V2-4 = Early repolarization.  
Within normal limits for age

#### Adult

QRS axis mean +50, range 0 to +100  
Dominant LV  
T waves upright across praecordial leads

## Additional reading

1. Davignon A, Rautaharju P, Boiselle E, Soumis F, Megelas M, Choquette A. Normal ECG standards for infants and children. *Pediatric Cardiology.* 1979;1:123–131.
2. Emmanouilides GC, Moss AJ, Adams FH. The electrocardiogram in normal newborn infants: correlation with hemodynamic observations. *J Pediatr.* 1965;67:578–87.[PubMed: 5832553]
3. Sreenivasan VV, Fisher BJ, Liebman J, Downs TD. Longitudinal study of the standard electrocardiogram in the healthy premature infant during the first year of life. *Am J Cardiol.* 1973;31:57–63.[PubMed: 4682410]
4. Garson A. Electrocardiography. In: Anderson RH, Macartney FJ, Shinebourne EA, Tynan M, editors. *Paediatric Cardiology.* Edinburgh: Churchill Livingstone; 1987. pp. 235–317.
5. Garson A. *The Electrocardiogram in Infants and Children: A systematic approach.* Lea Feibiger. 1983
6. Myung K, Park MK, Guntheroth WG. St. Louis: Mosby Year Book; 1992. *How To Read Pediatric ECGs.*

© Images in  
Paediatric Cardiology  
(1999-2012)

