

<b>IMAGES</b>	<b>in PAEDIATRIC CARDIOLOGY</b>
---------------	---

*Images Paediatr Cardiol.* 2008 Apr-Jun; 10(2): 11–17.

PMCID: PMC3232589

## **Transcatheter closure of symptomatic aortopulmonary window in an infant**

F Pillekamp,<sup>1</sup> T Hannes,<sup>1</sup> D Koch,<sup>2</sup> K Brockmeier,<sup>1</sup> and N Sreeram<sup>1</sup>

<sup>1</sup>Pediatric Cardiology, University of Cologne, 50931 Cologne, Germany

<sup>2</sup>Pediatric Cardiologist, 51607 Cologne, Germany

**Contact information:** N. Sreeram, Pediatric Cardiology, University Hospital of Cologne, Kerpenerstraße 62, 50937 Cologne, Germany Tel.: ++49-(0)-221-47886301 Fax: ++49-(0)-221-47886302 ; Email: n.sreeram@uni-koeln.de

Copyright : © Images in Paediatric Cardiology

This is an open-access article distributed under the terms of the Creative Commons Attribution-Noncommercial-Share Alike 3.0 Unported, which permits unrestricted use, distribution, and reproduction in any medium, provided the original work is properly cited.

### **Abstract**

An aortopulmonary window is a rare congenital cardiac defect. In the majority of symptomatic neonates and infants, primary surgical repair is the treatment of choice. In selected infants, catheter closure of the defect with a device may be feasible. We report on the successful closure of an AP window in a 12 month old infant, using a 6mm Amplatzer septal occluder. The procedure and follow-up were uneventful.

**MeSH:** Heart Catheterization, Prosthesis Implantation/instrumentation/methods, Heart defects, congenital, Blood Vessel Prosthesis Implantation

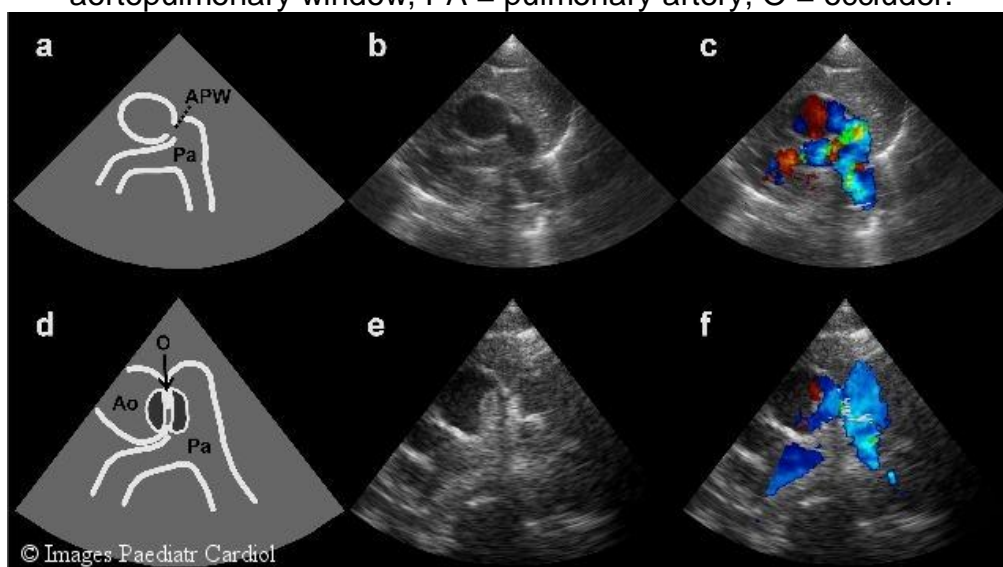
## Introduction

Aortopulmonary window is a rare congenital cardiac malformation that typically requires surgical treatment. We report on an infant with an intermediate-type of aortopulmonary window who presented with mild clinical signs of heart failure, in whom catheter occlusion was successfully achieved with a 6mm Amplatzer septal occluder at one year of age.<sup>1</sup>

## Case Report

The patient presented to the cardiologist with a murmur at 6 weeks of age. Minimal feeding difficulties were also present. The 12 lead electrocardiogram showed mild biventricular hypertrophy. Two-dimensional echocardiography identified an aortopulmonary window (diameter varying between 4 and 6mm) with a turbulent left-to-right shunt and a peak Doppler gradient of > 50 mmHg (Fig. 1).

Figure 1 Two-dimensional echocardiography before and after intervention. (a) Schematic illustration and (b) two-dimensional high parasternal short-axis view demonstrating the defect and, (c) Doppler colour flow image with left-to-right shunt. (d) Schematic illustration and (e) two-dimensional high parasternal short-axis view showing the position of the occluder. (f) Doppler colour flow image without residual left-to-right shunt. The protrusion into the main pulmonary artery does not disturb the normal flow pattern. AO = aorta, APW = aortopulmonary window, PA = pulmonary artery, O = occluder.



The left atrium and ventricle were enlarged. Anticongestive medication with furosemide (1 mg/kg d) and spironolactone (3 mg/kg d) was started. Serial echocardiographic studies continued to show a restrictive defect, without evidence for pulmonary hypertension. At 12 months of age (body weight: 9.2 kg) cardiac catheterization was performed to electively close the defect.

### Procedure

Under general anesthesia, the femoral artery and vein were percutaneously cannulated. heparin (100 units/kg) was administered after vascular access

F Pillekamp, T Hannes, D Koch, K Brockmeier, and N Sreeram. Transcatheter closure of symptomatic aortopulmonary window in an infant. *Images Paediatr Cardiol.* 2008 Apr-Jun; 10(2): 11–17.

was obtained. Ascending aortography demonstrated a 5mm aortopulmonary window (Fig. 2,3).

Figure 2 Aortic root angiogram prior to defect closure, in the anteroposterior and lateral views. An aortopulmonary window, 4.8 mm in size with immediate, significant opacification of the pulmonary artery tree from the aortic injection is seen..

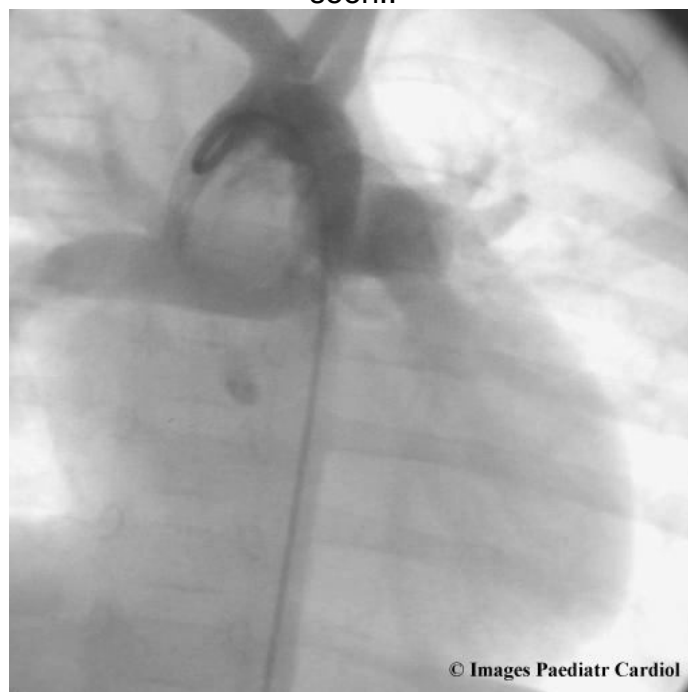
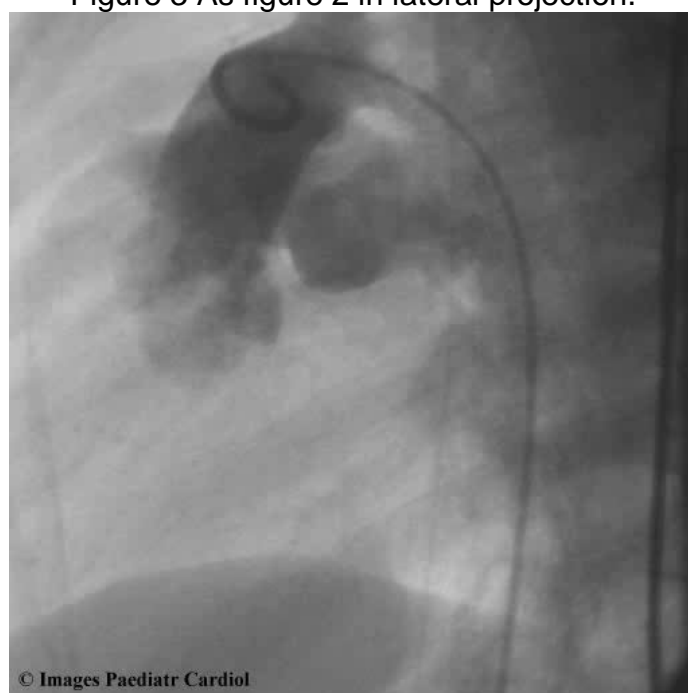


Figure 3 As figure 2 in lateral projection.



The defect was passed using a 4F Judkin's right coronary catheter and 0.035" Terumo wire (Terumo Corporation, Japan) combination. The Terumo wire was exchanged for a 300cm long 0.035" guidewire (noodlewire, Aga Medical Corporation, USA) in the right pulmonary artery. This wire was snared in the right pulmonary artery with a 10mm multi-snare (pfm, Cologne, Germany) snare introduced via the femoral vein, and exteriorised to create a continuous arteriovenous loop.

Over this wire, a 6F Amplatzer delivery system (Aga Medical Corporation, USA) was advanced from the femoral vein, and through the AP window into the descending aorta. A 6mm Amplatzer septal occluder was introduced into the delivery catheter, and the distal (left atrial) disk was opened in the aorta. The device was then retracted towards the defect, and the proximal (right atrial) disk was opened on the pulmonary arterial side of the defect. Appropriate device position was confirmed both by transthoracic echocardiography (Fig. 1) and aortography, prior to release of the device (Fig. 4,5).

Invasive pressure measurements in the aorta excluded any obstruction of the aorta by the device, and colour Doppler echocardiography confirmed lack of obstruction of the pulmonary arteries.

The procedure was uncomplicated. The patient was discharged from hospital on the following day, taking oral acetylsalicylic acid (aspirin 5 mg/kg day) for 6 months.

Figure 4 Aortogram after defect closure, showing the position of the device and a minimal residual leak. The coronary arteries were not affected by the intervention..

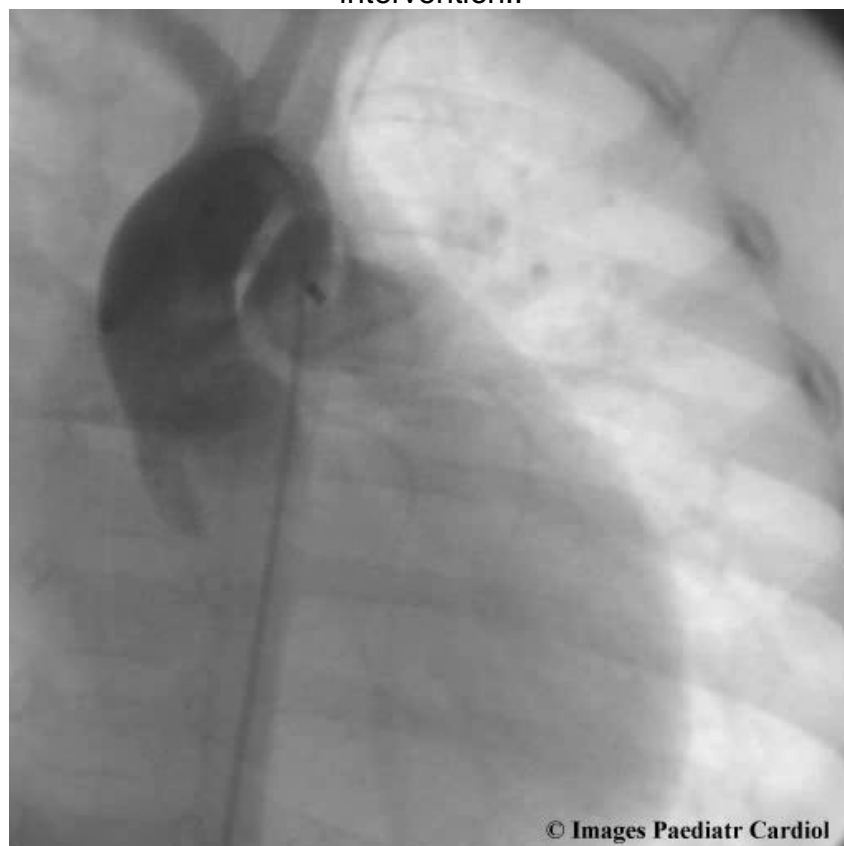
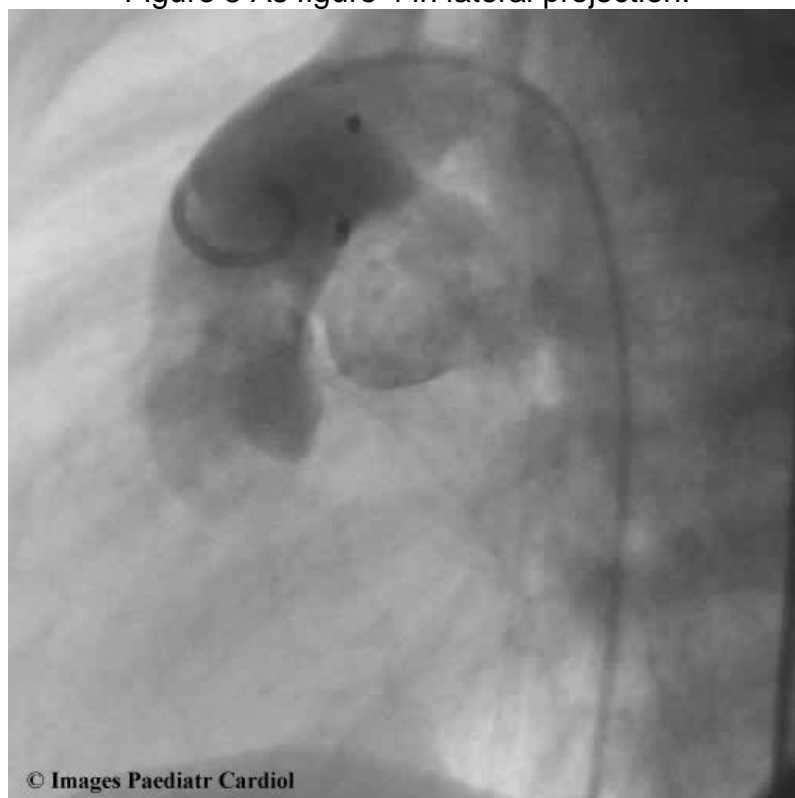


Figure 5 As figure 4 in lateral projection.



## Discussion

Aortopulmonary window is a rare congenital heart defect occurring in 0.1-0.2% of patients with congenital heart disease.<sup>2-4</sup> In about half the patients other cardiac abnormalities, especially an interruption of the aortic arch type A, may be associated with an aortopulmonary window.<sup>2,4</sup> Large defects resulting in severe left-to-right shunting typically present within the first weeks or months of life because of congestive heart failure. In contrast, a heart murmur without symptoms might be the only sign in small lesions. Early surgical treatment is recommended for the larger defects, to avoid the risk of progressive pulmonary vascular disease, but requires the use of cardiopulmonary bypass.<sup>5,6</sup> In the absence of evidence for pulmonary hypertension, it may be justifiable to delay treatment.

There have been isolated reports of transcatheter closure of aortopulmonary windows.<sup>7-9</sup> The majority however, have either been small defects, or have been closed beyond infancy.<sup>7-9</sup> With current advances in interventional catheterisation techniques and devices used to occlude intracardiac shunts, such defects may also be closed relatively early in life by percutaneous catheterisation. In considering defects amenable for transcatheter closure, it is important to bear in mind the relationship of the coronary artery origins to the

F Pillekamp, T Hannes, D Koch, K Brockmeier, and N Sreeram. Transcatheter closure of symptomatic aortopulmonary window in an infant. *Images Paediatr Cardiol.* 2008 Apr-Jun; 10(2): 11–17.

margins of the window. More distally located defects are ideal for catheter closure, and do not carry the risk of the device impinging on a coronary artery. An Amplatzer PDA device might also be a good alternative to the use of the ASD device as reported here. No obstruction to aortic or pulmonary flow has been reported in any of the descriptions of device closure of aortopulmonary windows to date.

## References

1. Jacobs JP, Quintessenza JA, Gaynor JW, Burke RP, Mavroudis C. Congenital Heart Surgery Nomenclature and Database Project: aortopulmonary window. *Ann Thorac Surg*. 2000;69(4 Suppl):S44–49.[PubMed: 10798415]
2. Bagtharia R, Trivedi KR, Burkhart HM, Williams WG, Freedom RM, Van Arsdell GS, et al. Outcomes for patients with an aortopulmonary window, and the impact of associated cardiovascular lesions. *Cardiol Young*. 2004;14:473–480.[PubMed: 15680067]
3. Jansen C, Hruda J, Rammeloo L, Ottenkamp J, Hazekamp MG. Surgical repair of aortopulmonary window: thirty-seven years of experience. *Pediatr Cardiol*. 2006;27:552–556.[PubMed: 16933063]
4. Kutsche LM, van Mierop LHS. Anatomy and pathogenesis of aorticopulmonary septal defect. *Am J Cardiol*. 1987;59:443–447.[PubMed: 3812313]
5. Backer CL, Mavroudis C. Surgical management of aortopulmonary window: a 40-year experience. *Eur J Cardiothorac Surg*. 2002;21:773–779.[PubMed: 12062263]
6. McElhinney DB, Reddy VM, Tworetzky W, Silverman NH, Hanley FL. Early and late results after repair of aortopulmonary septal defect and associated anomalies in infants <6 months of age. *Am J Cardiol*. 1998;81:195–201.[PubMed: 9591904]
7. Tulloh RM, Rigby ML. Transcatheter umbrella closure of aorto-pulmonary window. *Heart*. 1997;77:479–480. [PMCID: PMC484774][PubMed: 9196422]
8. Atiq M, Rashid N, Kazmi KA, Qureshi SA. Closure of aortopulmonary window with Amplatzer duct occluder. *Pediatr Cardiol*. 2003;24:298–299.[PubMed: 12687300]
9. Naik GD, Chandra VS, Shenoy A, Isaac BC, Shetty GG, Padmakumar P, et al. Transcatheter closure of aortopulmonary window using Amplatzer device. *Cathet Cardiovasc Intervent*. 2003;59:402–405.

