

# IMAGES

## in PAEDIATRIC CARDIOLOGY

Johnson BV, Mook L, Johnston T. Diagnosis and treatment of hereditary hemorrhagic telangiectasia in a pediatric patient with chronic cyanosis. *Images Paediatr Cardiol* 2016;18(1):1-7.  
University of Washington School of Medicine.

### **Background**

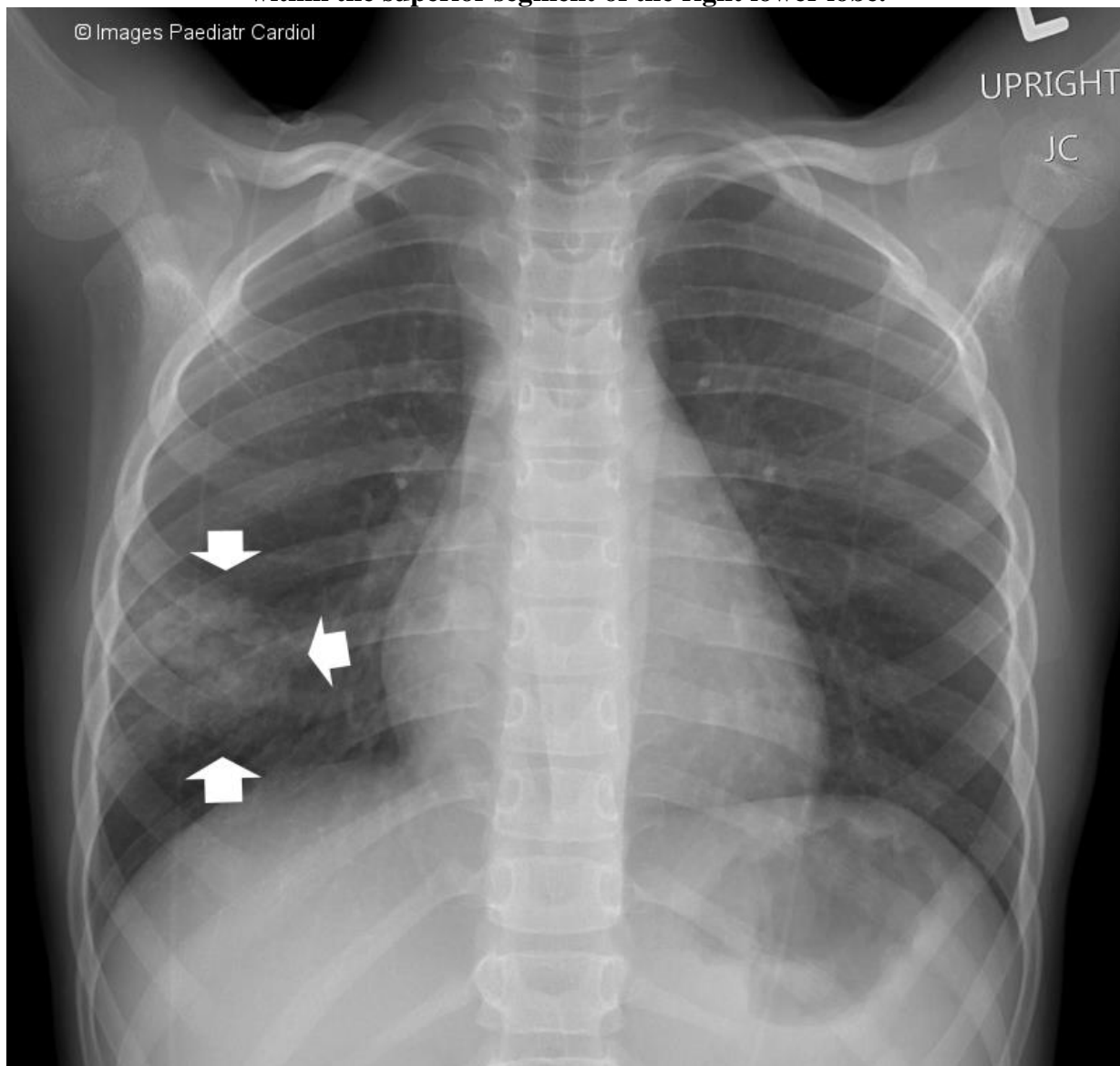
Hereditary hemorrhagic telangiectasia (HHT) is an autosomal dominant disorder of vascular dysplasias that is characterized by mucocutaneous telangiectasias, gastrointestinal tract bleeding, and arteriovenous malformations (AVMs) of the pulmonary, hepatic, and cerebral vascular systems.

### **Case Summary**

A seven-year-old boy presented to his primary care provider with a five-day history of watery diarrhea and was incidentally found to have oxygen saturations in the low eighties, perioral cyanosis, and clubbing on physical exam. He was referred to the pediatric emergency department (ED) for evaluation. Upon presentation to the pediatric ED, oxygen saturation ranged from 74-85%. He was in no acute distress and was afebrile with normal vital signs. The patient was small for his age with height and weight in the thirteenth and third percentiles, respectively, and had central cyanosis and clubbing of fingers and toes. Auscultation revealed diminished lung sounds in the right lower lobe. No mucocutaneous telangiectasias or cardiac murmurs were appreciated. Family history was positive for hereditary hemorrhagic telangiectasia (HHT) with gastrointestinal bleeding and anemia in his maternal great grandmother and maternal grandmother, minor bleeding and mucocutaneous telangiectasias in his mother, and cyanosis with exercise and recurrent epistaxis in his brother.

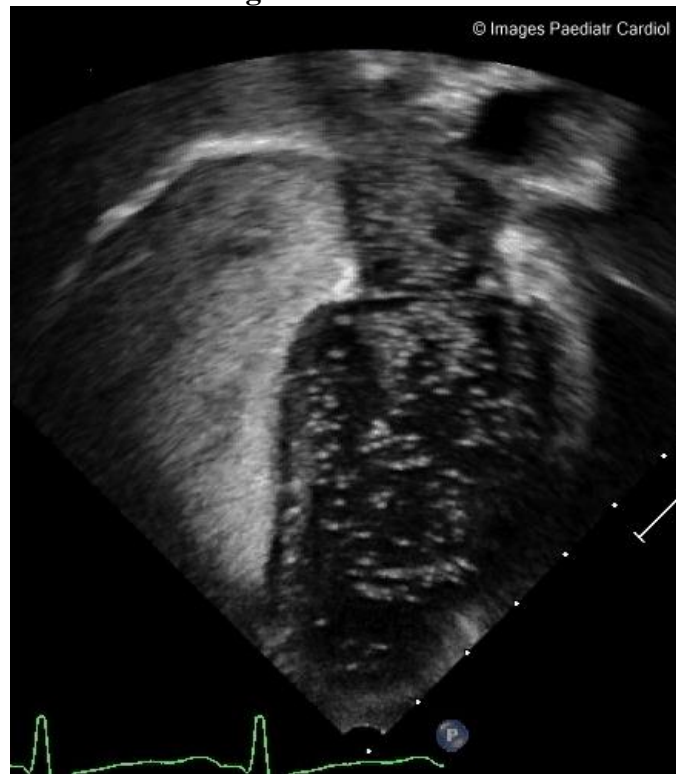Complete blood count was significant for a hemoglobin level of 18.1 g/dL. A chest x-ray (Figure 1) showed an airspace opacification within the superior segment of the right lower lobe suspicious for an arteriovenous malformation (AVM).

**Figure 1. Chest x-ray during initial evaluation demonstrating airspace opacification (arrows) within the superior segment of the right lower lobe.**



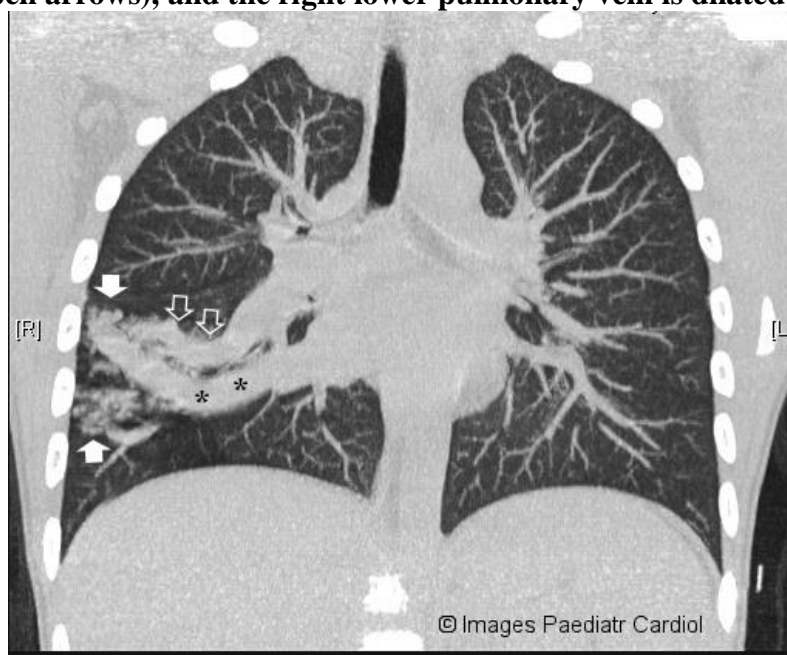
An echocardiogram with bubble study was performed at the bedside in the ED and was positive with a large volume of bubbles in the left heart, consistent with a right-to-left shunt (Figure 2).

**Video 1. Echocardiography conducted at the bedside with positive bubble study, confirming a right-to-left shunt.**

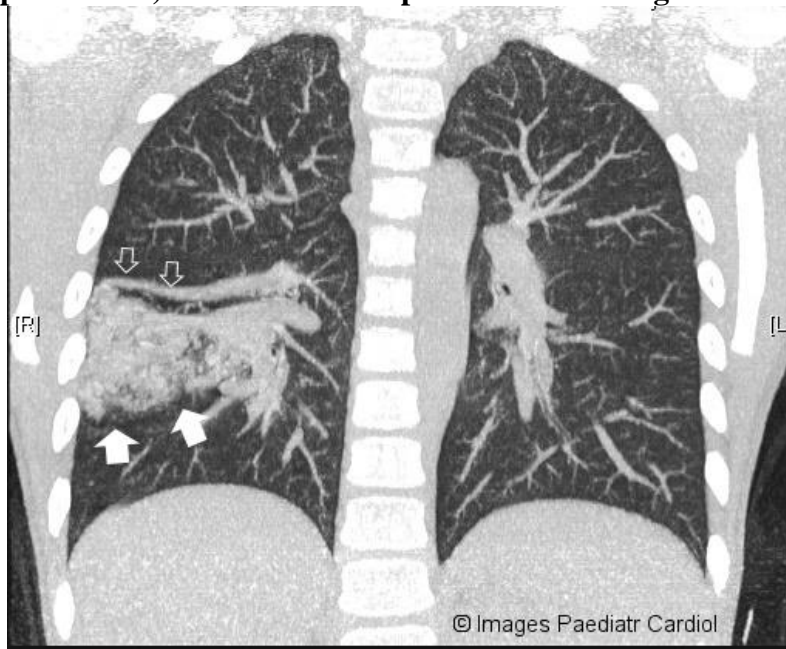


A chest CT demonstrated clusters of round opacities in the right lower lobe with a large feeding artery originating from the right interlobar artery and an enlarged left lower pulmonary vein, consistent with a dominant AVM (Figures 3 & 4).

**Figure 3. Anterior thoracic computed tomography scan illustrating a dominant pulmonary arteriovenous malformation (solid arrows) in the right lower lung lobe. There is a large feeder vessel (open arrows), and the right lower pulmonary vein is dilated (asterisk).**

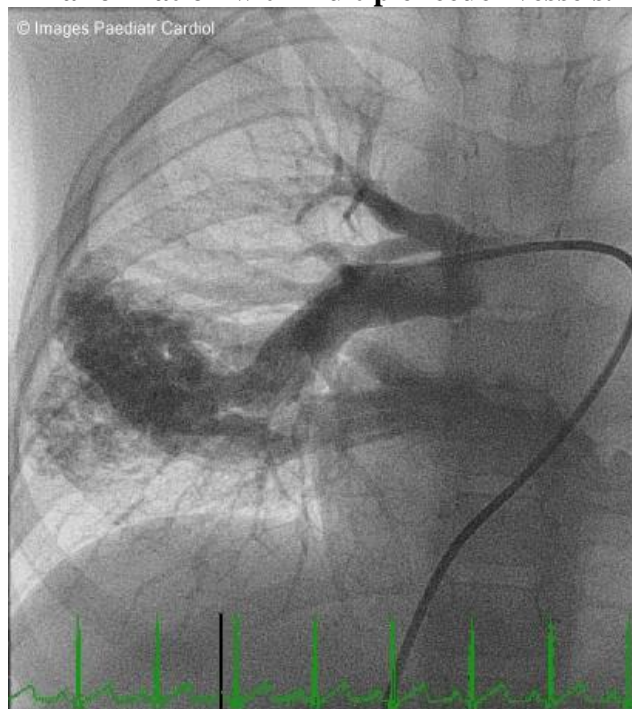

**Figure 4. Posterior thoracic computed tomography scan illustrating a dominant pulmonary arteriovenous malformation (solid arrows) in the right lower lung lobe. There is a small feeder vessel (open arrows) which is more superior than the larger vessel seen in figure 2.**



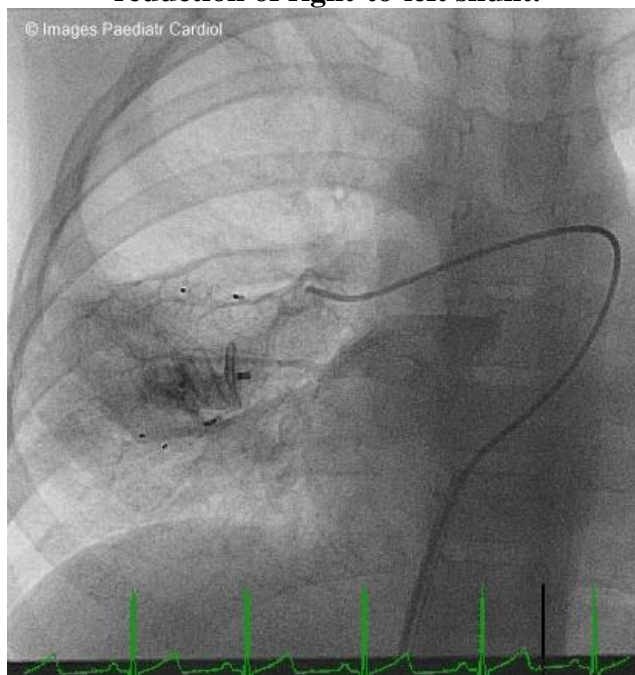
The patient underwent percutaneous right heart catheterization. Angiography of the right pulmonary artery revealed an AVM with a large feeder vessel, approximately 7mm in diameter, and several smaller feeder vessels (figure 5).

**Figure 5. Angiography of the right pulmonary demonstrating a large arteriovenous malformation with multiple feeder vessels.**



A 12mm plug was placed in the larger vessel and three 4mm plugs were placed in other feeder vessels, which can be seen post-embolization via angiogram (figure 6).

**Figure 6: Angiography of the right pulmonary artery post-embolization illustrating effective reduction of right-to-left shunt.**



A few smaller vessels that fed the AVM were identified but we decided not to occlude them due to their small size. Two hours post-procedure, the patient was awake and alert in bed. His oxygen saturation was 95%, and his digital and peri-oral cyanosis had resolved. At one-month follow-up, the patient was doing well; he remained acyanotic and his oxygen saturation was 90%. At future follow-up visits we will assess the need for additional embolization of the smaller feeder vessels noted on angiography post-embolization. The patient and his family were also encouraged to follow up with the hospital's genetics service for further evaluation and potential screening for hepatic and brain AVMs.

## Discussion

Hereditary hemorrhagic telangiectasia (HHT), or Osler-Weber-Rendu syndrome, is an autosomal dominant disease of vascular dysplasias, classically characterized by mucocutaneous telangiectasias and vascular malformations. The disease was initially described in the late 19<sup>th</sup> century as a familial disorder of cutaneous telangiectasias, recurrent epistaxis, and gastrointestinal bleeding,<sup>1-3</sup> which are the most common presenting signs of the disease. HHT has since been understood to cause visceral arteriovenous malformations (AVMs) in the pulmonary, hepatic, and cerebral vascular system, as well<sup>4</sup>.

HHT's prevalence is estimated to be one in 5,000-10,000,<sup>4,5</sup> with some reports suggesting an even higher frequency.<sup>6</sup> Clinical manifestations of HHT depend on which of the above vascular dysplasias are present in an individual, and penetrance is age-related with complete penetrance generally manifesting by age 40.<sup>5</sup> Frequent epistaxis, which is the most common complaint, begins at an average of 12 years of age,<sup>7</sup> and mucocutaneous telangiectasias often present after the onset of epistaxis. Pulmonary AVMs are reported to occur in 40-60% of affected individuals,<sup>4,5</sup> and they more commonly present in a younger population than hepatic or cerebral AVMs.<sup>8</sup>

Diagnosis of HHT is commonly based on clinical manifestations and family history, but can now also be made based on genetic testing. The clinical diagnosis depends on four criteria as defined by the Curaçao Criteria:<sup>9</sup> recurrent epistaxis, telangiectasias at characteristic sites (lips, oral cavity,

fingers, nose), visceral lesions identified via diagnostic imaging, and family history in a first-degree relative. Diagnosis of HHT is “definite” if three or more criteria are present and “suspected” if two criteria are present. Genetic testing is now also available, which allows for familial diagnosis and may aid in diagnosing relatives who do not yet meet clinical diagnostic criteria. All HHT cases with an identified genetic cause are believed to be due to mutations in transforming growth factor beta (TGF- $\beta$ ) signaling. At least 85% of cases are caused by mutations in the endoglin gene (ENG) and activin-A receptor type II-like 1 gene (ACVRL1),<sup>6,10</sup> and a small number of HHT cases have recently been attributed to mutations identified in the SMAD4 and GDF2 genes, as well.

Screening for visceral involvement is recommended for all patients diagnosed with HHT due to the potentially devastating complications of pulmonary, cerebral, and hepatic AVMs.<sup>6</sup> Pulmonary AVMs are most commonly confirmed via thoracic CT or transthoracic contrast echocardiography (TTCE) with bubble study, although a chest radiograph may be used as a first-line screening test due to its efficiency and low cost.<sup>5</sup> In contrast, cerebral AVMs are often diagnosed via MRI to minimize brain radiation, and hepatic AVMs can be diagnosed by Doppler sonography, MRI, or CT.<sup>6</sup>

Treatment of patients with HHT varies by individual features of the disease. Experts recommend that all pulmonary AVMs be treated due to the potential for development of cyanosis, stroke, heart failure, or pulmonary hemorrhagic complications.<sup>6</sup> Percutaneous transcatheter embolization of pulmonary AVMs is now the most common method of treatment. Catheter based therapy is effective and less invasive than traditional surgical techniques.<sup>5</sup> Similarly, cerebral AVMs are often treated via embolization and/or microsurgery and stereotactic radiation with high operational risk, and hepatic AVMs are treated via hepatic artery embolization or liver transplantation with variable results/effectiveness.<sup>6</sup>

This case was unique because the patient presented with only signs of chronic cyanosis and no history of epistaxis, mucocutaneous telangiectasias, gastrointestinal bleeding, or iron-deficient anemia. However, given his family history of one or more of these symptoms for four consecutive generations, clinical suspicion was high that his cyanosis was due to a pulmonary AVM caused by underlying HHT. The presence of an AVM was screened for via chest x-ray and confirmed via TTCE and thoracic CT. The patient was treated via percutaneous catheterization and embolization of the largest feeder vessels with great clinical effect, as demonstrated by resolution of cyanosis. Overall, this case illustrates efficient diagnosis and treatment of a patient with suspected HHT who presented without the traditional signs of the disease. Given the patient’s young age he is at high risk of developing additional AVMs in the future,<sup>8</sup> so close follow-up and monitoring is encouraged.

## **References**

1. Osler W. On a family form of recurring epistaxis, associated with multiple telangiectases of the skin and mucous membranes. *Bulletin of the Johns Hopkins Hospital*. 1901;12.
2. Weber FP. Multiple Hereditary Developmental Angiomata with Recurring Epistaxis. *Proc R Soc Med*. 1908;1(Clin Sect):65-66.
3. Rendu H. Epistaxis repetees chez un sujet porteur de petits angiomes cutanes et muquez. *Gazette des Hopitaux Civils et Militaires (Paris)*. 1896;135.
4. Garg N, Khunger M, Gupta A, Kumar N. Optimal management of hereditary hemorrhagic telangiectasia. *J Blood Med*. 2014;5:191-206.
5. Lacombe P, Lacout A, Marcy PY, et al. Diagnosis and treatment of pulmonary arteriovenous malformations in hereditary hemorrhagic telangiectasia: An overview. *Diagn Interv Imaging*. 2013;94:835-848.



Johnson BV, Mook L, Johnston T. Diagnosis and treatment of hereditary hemorrhagic telangiectasia in a pediatric patient with chronic cyanosis. *Images Paediatr Cardiol* 2016;18(1):1-7.

6. Faughnan ME, Palda VA, Garcia-Tsao G, et al. International guidelines for the diagnosis and management of hereditary haemorrhagic telangiectasia. *J Med Genet*. 2011;48:73-87.
7. Aassar OS, Friedman CM, White RI. The natural history of epistaxis in hereditary hemorrhagic telangiectasia. *Laryngoscope*. 1991;101:977-980.
8. Plauchu H, de Chadarevian JP, Bideau A, Robert JM. Age-related clinical profile of hereditary hemorrhagic telangiectasia in an epidemiologically recruited population. *Am J Med Genet*. 1989;32:291-297.
9. Shovlin CL, Guttmacher AE, Buscarini E, et al. Diagnostic criteria for hereditary hemorrhagic telangiectasia (Rendu-Osler-Weber syndrome). *Am J Med Genet*. 2000;91:66-67.
10. McDonald J, Wooderchak-Donahue W, VanSant Webb C, Whitehead K, Stevenson DA, Bayrak-Toydemir P. Hereditary hemorrhagic telangiectasia: genetics and molecular diagnostics in a new era. *Front Genet*. 2015;6:1.

### Contact Information

© Images in  
Paediatric Cardiology  
(1999-2016)

Bryce Johnson  
MS-3  
University of Washington  
School of Medicine  
[bryce08@uw.edu](mailto:bryce08@uw.edu)

