

# IMAGES

## in PAEDIATRIC CARDIOLOGY

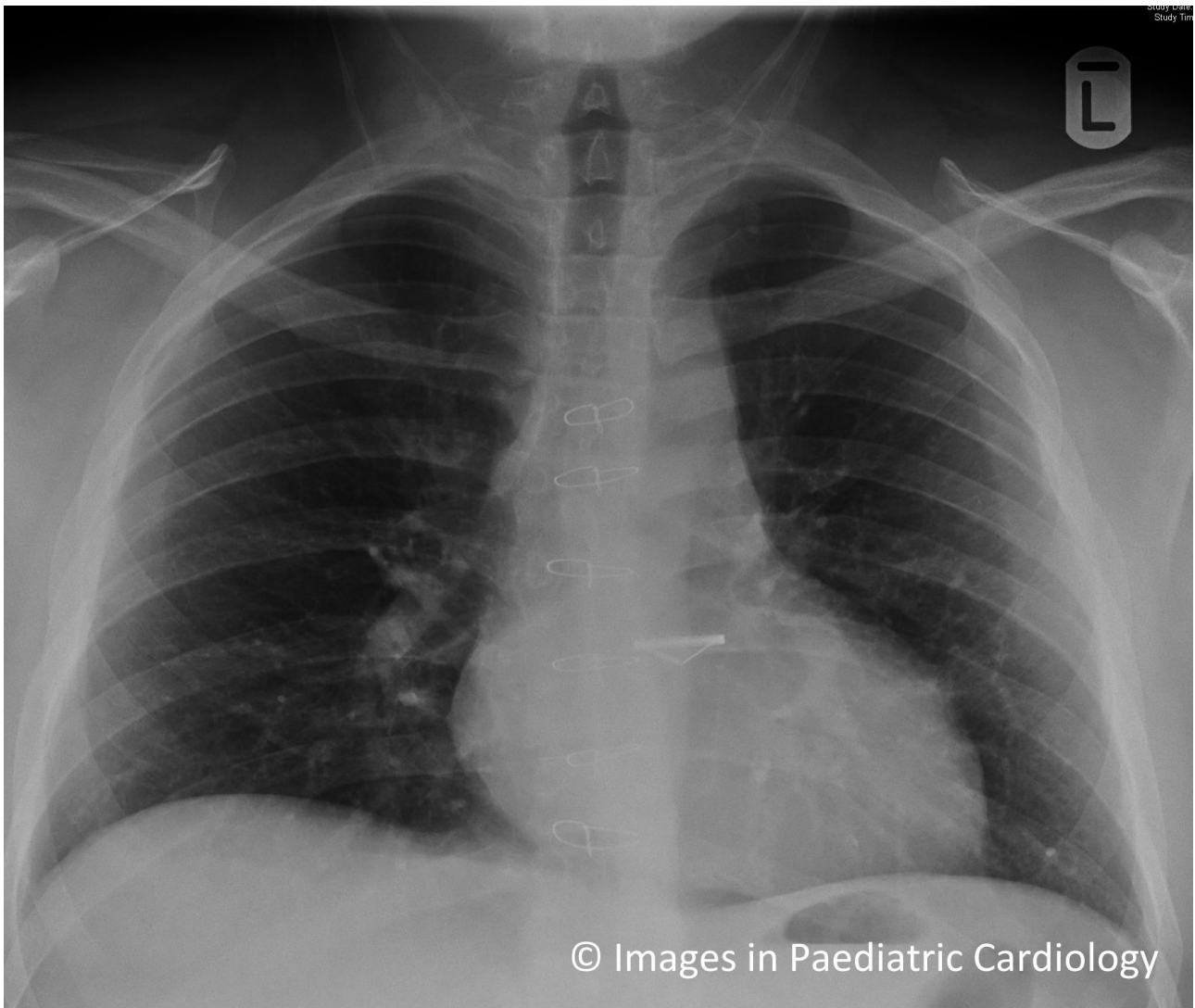
Somerville J, Grech V. The chest x-ray in congenital heart disease 7. *Images Paediatr Cardiol* 2016;18(1):8-9.

Cardiology Department, Mater Dei Hospital, Malta.

This CXR shows a normal vascular pedicle with a left aortic knuckle and normal pulmonary vascularity. There is some prominence of the apex to the left with a rounded contour suggestive of left ventricular enlargement.

There is no evidence of either atria being abnormally placed or distorted. An interesting point is that the patient has an aortic valve replacement and the disk valve prosthesis lies in an unusual and high horizontal position. This suggests that aortic valve is in unusual position such as in transposition of great arteries following an arterial switch procedure.

This is the case in this patient wherein aortic valve replacement was carried out for aortic regurgitation.



**Contact Information**

© Images in  
Paediatric Cardiology  
(1999-2016)

Victor Grech  
Cardiology Department  
Mater Dei Hospital  
Malta  
[victor.e.grech@gov.mt](mailto:victor.e.grech@gov.mt)

